

Distraction Osteogenesis – Evolution & Technique- An Overview

Dr. Siddharth Sharma¹, Dr. Abhishekrathi², Dr. Gaurav Mittal³,
Dr. Rakesh Ranjan⁴

¹Senior Lecturer – OMFS Institute Of Dental Studies & Technologies, UP

²Senior Lecturer – OMFS Institute Of Dental Studies & Technologies, UP

³Professor & Head- OMFS Institute Of Dental Studies & Technologies, UP

⁴Post Graduate – Iind Year Institute Of Dental Studies & Technologies, UP

Abstract: Distraction osteogenesis is a novel method for neo-tissue generation which involves development of both hard and soft tissue under applied force in certain direction. The major advantage of this procedure is diminishing reliability on grafting for reconstruction hence lack of donor site morbidity. Myriad of applications of distraction osteogenesis are present in maxillofacial surgery field which include mandibular distraction, midfacial distraction, alveolar ridge augmentation for functional, aesthetic and rehabilitative purpose.

Keywords: distraction, craniofacial distraction, alveolar distraction

I. Introduction

Distraction Osteogenesis (DO), also called callus distraction, callotaxis, osteodistraction, and distraction histogenesis is a biological process of regenerating neo formed bone and adjacent soft tissue by gradual and controlled traction of the surgically separated bone segments¹. Specifically, this process is initiated when a traction force is applied to the bone segments and continues as long as the callus tissues are stretched. This traction force, in turn, generates tension within the tissues that connect the bone segments, which stimulates new bone formation parallel to the vector of distraction. Importantly, distraction forces applied to the bone also create tension in the surrounding soft tissues, initiating a sequence of adaptive changes termed distraction histogenesis. Under the influence of tensional stress produced by gradual bone distraction, active histogenesis occurs in different tissues.

Hippocrates described the placement of traction forces on broken bones(460 BC). The first occurrence of continuous traction for long bone fractures can be traced to the work of de Chauillac in the 14th century, who used a pulley system that consisted of a weight attached to the leg by a cord. Barton, in 1826 is credited with being the first to perform a surgical division of bone or osteotomy. The development of external skeletal fixation dates from the middle of the nineteenth century when Malgaigne constructed an apparatus that was directly attached to bone, thereby allowing direct transmission of mechanical force to the skeleton.²

In 1991 Ilizarov postulates, which, are now considered as principal of distraction, that gradual traction creates stress that can stimulate and maintain regeneration and active growth of living tissues. Clinically, after distraction newly formed bone rapidly remodels to conform to the bone's natural structure. The second Ilizarov principle theorized that the shape and mass of bones and joints are dependent on an interaction between mechanical loading and blood supply³⁻⁶

II. Review Of Literature

Distraction devices

McCarthy, in 1989, was the first to clinically apply an external fixation device for mandibular lengthening⁷ followed by Klein in 1994 which was modification of an orthopedic distractor, Hoffman Mini Lengthener (Stryker Leibinger, Kalamazoo, MI, USA) attached to the osteotomized bone segments with two pairs of 2 mm half pins(Fig 1). Perrott et al used Synthes Mini Lengthening Apparatus which is another mini version of an orthopedic apparatus consisting of two double-pin clamps connected by a linear telescopic distractor⁸(Fig2). The Orthofix Mini Fixator consists of a sliding clamp directly attached to the distraction mechanism and a rotating clamp connected to the body of the apparatus by a special ball-and-socket joint⁹. Bitter and Klein introduced Uni-directional Mandibular Distractor¹⁰(Fig 3). Despite of the success of osteodistraction, external devices were capable of uni-directional mandibular lengthening only, either horizontal or vertical. Molina and Ortiz-Monasterio were the first to use bi-directional osteodistraction in the mandible this allows 2 independent sites of distraction¹¹(Fig 4). Multiplanar distractor used by McCarthy consists of two distraction rods with gradually sliding clamps connected in the middle by a universal hinge¹². The need to miniaturize and modify the available orthodontic expansion appliance led to the development of intraoral mandibular distractor¹³. In 1987, Guerrero applied the first intraoral tooth-borne appliance for osteodistraction of the mandibular symphysis. In 1990, he reported the results of intraoral mandibular widening

on eleven patients with transverse deficiencies ranging from 4 to 7 mm¹⁴. In 1994, McCarthy and coworkers developed a miniaturized bone-borne Uniguide™ Mandibular Distraction Device suitable for intraoral placement which consisted of two clamps that were attached to the bone via pairs of pins connected by a telescopic distraction rod.¹⁵ Wangerin in Germany designed a similar appliance which consists of two mini plates for bone fixation connected by a square-shaped distraction cylinder¹⁶(Fig 5). In 1996, Wangerin et al and French surgeons Diner and Vazquez in 1997, followed by Hoffmeister in 1998, introduced two updated intraoral bone-borne devices for mandibular lengthening based on the anatomic location of distraction site - horizontal corpus or ascending ramus. The DynaForm Intraoral Distractor developed by Guerrero and Bell introduced an intraoral distractor that could be universally adapted¹⁷. The Modular Internal Distraction System or MID System, developed in conjunction with Cohen, permits, distraction and manipulation of the entire craniofacial skeleton, including the midface, cranium, and mandible¹⁸. Razdolsky developed a series of tooth-borne and hybrid ROD devices in which the anteriorly activated distraction mechanism can be attached to stainless steel crowns or mini plates by removable attachments¹⁹.

Distraction osteogenesis has found its application in rehabilitating alveolar defects. The first vertical distraction device, the LEAD System, was designed by Chin²⁰(Fig 6). Gaggl and Rainer used a SIS-Distraction device for vertical alveolar distraction to treat edentulous alveolar ridges and alveolar defects due to traumatic tooth loss²¹. Hidding, Lazar, and Zoller from Germany developed the Vertical Distractor for alveolar ridge augmentation.²²

Technique

Distraction osteogenesis begins with the development of a reparative callus. The callus is placed under tension by stretching, which generates new bone. As was previously alluded to, distraction osteogenesis consists of four sequential periods: 1) osteotomy, 2) latency (from bone division to the onset of traction), 3) distraction (time when gradual traction is applied and distraction regenerate is formed), and 4) consolidation (allows maturation and corticalization of the regenerate after traction forces are discontinued).

Bone division was initiated with a series of bicortical drill holes placed along the osteotomy line, which were then connected by a 3 mm osteotome²³ (Fig 7). Molina and Ortiz-Monasterio simplified the methods established by McCarthy. Their technique utilizes a corticotomy of the lateral aspect of the mandible that extends inferiorly around the edge of the mandible and superiorly toward the alveolar ridge, thereby leaving the medial cortical plate intact²⁴. It consists of lag phase which is typically 5-7 days although in neonates and infants the latency period may be omitted or last only 24hrs owing to their high metabolic activity²⁵. Distraction phase in which rate of distraction is typically 1mm/day while some advocate up to 2mm/day in younger children to avoid early consolidation and a slower rate of .25 to .5mm/day in older pt^{25, 26, 27}. Followed by distraction, consolidation phase for which 6-8 weeks is considered adequate²⁸. Retention phase is when the device is removed and its stability is maintained typically with assistance of orthodontic appliance. Apart from jaw distraction, it has its application in implantology. Oh and Ryu's protocol for alveolar ridge augmentation included latency period of 7 days followed by 0.5 mm distraction 2 times per day followed by 4 weeks of consolidation.

III. Discussion

The successful application of the distraction osteogenesis technique is equally dependent on biological and biomechanical factors. The basic biological factors include a lower-power osteotomy with maximum preservation of osteogenic tissues including the periosteal and endosteal blood supply, an adequate duration of the latency period to allow development of the fracture callus, an optimal rate and rhythm of distraction, and a sufficient time for remodeling of the newly formed bone prior to unrestrained functional loading. The biomechanical parameters of distraction can be divided into several categories: extrinsic or fixator-related factors, intrinsic or tissue-related factors, orientation of the distraction vector, and device orientation.

During distraction osteogenesis, however, the normal process of fracture healing is interrupted by the application of gradual traction to the soft callus. The tension stress developed in the gradually stretched tissues stimulates changes at the cellular and sub-cellular levels. These changes can be characterized as a growth stimulating effect and a shape forming effect. The growth stimulating effect of tension activates the biologic elements of the intersegmentary connective tissue. This includes the prolongation of angiogenesis with increased tissue oxygenation, and increased fibroblast proliferation with intensification of biosynthetic activity. The shape forming effect of tension causes an altered phenotypic expression of the fibroblasts. These fibroblast-like cells are characterized by a hypertrophic appearance of their intermediate filaments. The shape forming effect also polarizes these "distraction" fibroblasts, orienting them and their secreted collagen parallel to the vector of distraction²⁹.

Between the 3rd and 7th day of distraction, capillaries grow into the fibrous tissues, thereby, extending the vascular network not only toward the center of the gap but also toward the medullary canal of both adjacent

bone segments. The newly formed capillary loops are parallel to each other as well as to the axis of distraction. During the 2nd week of distraction, primary osteons begin to form³⁰.

The osteoid-producing osteoblasts, located among the collagen fibers, lay down osteoid tissue on these collagen fibers and eventually become enveloped as bone spicules gradually enlarge by circumferential apposition of collagen and osteoid³¹. Osteogenesis is initiated at the existing bone walls and progresses toward the center of the distraction gap. By the end of the 2nd week, the osteoid begins to mineralize. After distraction ceases, the fibrous interzone gradually ossifies and one distinct zone of woven bone completely bridges the gap.³²

As the regenerate matures, the zone of primary osteons significantly decreases and is later resorbed completely. In the ensuing months, the initially formed bony scaffold is reinforced by parallel-fibered and lamellar bone. Haversian remodeling occurs representing the last stage of cortical reconstruction which eventually normalizes the bone structure³³. It takes a year or more before the structure of newly formed bony tissue is comparable to the preexisting bone³.

Indications for the application of distraction devices include: congenital or acquired hypoplasia of the mandibular corpus, ascending ramus, or the entire mandible, Hemifacial microsomia, Hemifacial microsomia, Pierre-Robin Syndrome, Treacher-Collins Syndrome, Crouzon Syndrome, Extreme facial asymmetries or mandibular shortening due to avascular necrosis or trauma, Mandibular retrognathic, severe anterior crowding, Brody syndrome or scissor bite, and impacted anterior teeth.

However caution needs to be exercised: If compliance of the patient with the distraction regime cannot be guaranteed, particularly when bulky extra-oral fixators are used, when an adequate bone stock which is necessary to accept the distraction appliances and to provide suitable opposing surfaces capable of generating a healing callus, is not available also, in cases where a particular deformity can be treated with conventional, time-tested, orthognathic surgery with equivalent result. DO is a lengthy procedure requiring close monitoring of the patient. The long course of treatment required for distraction and consolidation may result in intractable soft-tissue infection, bone infection, and psychological problems, other contraindications included-children under 6 years, osteoporosis, metal allergies, following tumor irradiation and certain neuropsychiatric disorder.

There have been reports of simultaneous use of both orthognathic surgery and distraction as treatment modalities to achieve treatment objective. Case has been reported where back distraction osteogenesis was performed to compensate for shortening of ramus which included execution of bilateral sagittal split osteotomy followed by placement of osteodistractor³⁵.

Distraction osteogenesis is an alternative modality for reconstruction of TMJ which utilizes the concept of transport distraction which involves moving a part of bone post osteotomy away from the host bone into the defect.³⁶

Craniofacial DO is a rapidly growing field of craniofacial reconstruction that has become an accepted method worldwide for the treatment of numerous congenital and acquired craniofacial anomalies. Clinical parameters that affect treatment outcome of craniofacial DO, include age, surgical technique, distraction rate and rhythm, latency period, contention period and distraction device. Distraction can be performed by isolated mandibular or maxillary distraction which includes either lengthening or/and transverse expansion e.g. class 2 malocclusion and unilateral or bilateral clefts respectively³⁷. Simultaneous mandibular and maxillary distraction is carried out in cases like hemifacial microsomia and Treacher Collins. Midfacial distraction which may include zygomatic arch expansion or advancement of midface with associated Le Fort III osteotomy and midface advancement without osteotomy. This may be carried out with or without cranial distraction in cases like that of Crouzon's and Apert's³⁸.

IV. Conclusion

Distraction osteogenesis is increasingly used for bone lengthening of craniofacial skeleton. Distraction osteogenesis not only provides a one-time solution for reconstruction of ramal-condylar unit but also omits the need of both interpositional substitute of disc and the donor graft. Since it does not require bone graft and enables simultaneously soft tissue distraction along with bony distraction, it is well suited for correction of craniomaxillofacial deformities.

Bibliography

- [1]. Cope JB, Samchukov ML, Cherkashin A M. Mandibular distraction osteogenesis: A historic perspective and future directions. *Am J Orthod Dentofacial Orthop* 1999; 115: 448-460.
- [2]. Samchukov ML, Cherkashin AM, Cope JB. Distraction osteogenesis: history and biologic basis of new bone formation. In: Lynch SE, Genco RJ, Marx RE (Eds.), *Tissue Engineering: Applications in Maxillofacial Surgery and Periodontics*. Carol Stream, Quintessence 1999; 131-146.
- [3]. Ilizarov GA. The tension-stress effect on the genesis and growth of tissues: Part I. The influence of stability of fixation and soft-tissue preservation. *Clin Orthop Relat Res* 1989; 238: 249-281.
- [4]. Ilizarov GA. The tension-stress effect on the genesis and growth of tissues: Part II. The influence of the rate and frequency of distraction. *Clin Orthop Relat Res*: 1989; 263-285.

- [5]. IlizarovGA.The principles of the Ilizarovmethod:BullHosp Joint Dis OrthopInst1988;48: 1-11.
- [6]. IlizarovGA.Clinical application of the tension-stress effect for limb lengthening. ClinOrthopRel Res: 1990;8-26.
- [7]. McCarthy JG.The role of distraction osteogenesis in the reconstruction of the mandible in unilateral craniofacial microsomia:ClinPlastSurg1994;21: 625-631
- [8]. Perrott D, Berger R, Vargervik K, KabanL.B.Use of a skeletal distraction device to widen the mandible:JOralMaxillofacSurg 1993; 435-439
- [9]. Pensler JM, Goldberg DP, Lindell B, Carroll NC.Skeletal distraction of the hypoplasticmandible:AnnPlastSurg 1995;34: 130-136.
- [10]. Neelam Andrade et al Development and evolution of distraction devices: Use of indigenous appliances for Distraction Osteogenesis-An overview Ann Maxillofac Surg. 2011 Jan-Jun; 1(1): 58–65
- [11]. Molina F, Ortiz MonasterioF.Mandibular elongation and remodeling by distraction. A farewell to major osteotomies:PlastReconstrSurg 1995; 96:825-842
- [12]. McCarthyJG, Williams JK, Grayson BH. Controlled multiplanar distraction of the mandible: device development and clinical application. J Craniofac Surg,1998; 9: 322-329.
- [13]. Cope JB, Samchukov ML, CherkashinAM.Mandibular distraction osteogenesis: A historic perspective and future directions:Am J OrthodDentofacialOrthop 1999;115: 448-460.
- [14]. Guerero CA, Bell WH, ContastiGI.Mandibular widening by intraoral distraction osteogenesis:Br J Oral MaxillofacSurg, 1997;35: 383-392
- [15]. McCarthy JG.The role of distraction osteogenesis in the reconstruction of the mandible in unilateral craniofacial microsomia:ClinPlastSurg1994;21: 625-
- [16]. Wangerin K, GroppH.Multidimensional intraoral distraction osteogenesis of the mandible – 4 years of clinical experience:Int. J. Oral Maxillofac. Surg 1997;26:14.
- [17]. Seiji iida et al maxillary anterior segmental distraction osteogernis with the dynaform system for severe maxillary retrusion in cleft lip and palate plastic and reconstructiue surgery sept 2007
- [18]. Cohen SR, Rutrick RE, Burstein FD.Distractionosteogenesis of human craniofacial skeleton: Initial experience with a new distraction system.:JCraniofacSurg 1995;6:368-74.
- [19]. Rzdolsky Y, Pensler JM, DessnerS.Skeletal distraction for mandibular lengthening with a completely intraoral tooth-borne distractor: A preliminary report. In: McNamara JA Jr, Trotman CA, editors. Distraction osteogenesis and tissue engineering. Ann Arbor, Michigan: Center for Human Growth and Development, The University of Michigan1998
- [20]. Chin M, Toth BA. Distraction osteogenesis in maxillofacial surgery using internal devices: review of five cases:J Oral MaxillofacSurg 1996;54: 45-53
- [21]. Gaggl A, Rainer H &ChiariFM.Horizontal distraction of the anterior maxilla in combination with bilateral sinus lift operation— preliminary report:Int J Oral MaxillofacSurg 2005;34: 37–44.
- [22]. Rajatmohanty et al Vertical alveolar ridge augmentation by distraction osteogenesis journal of clinical and diagnostic research 2015 dec ,vol-9(12)
- [23]. McCarthy JG, Schreiber J, Karp N, Thorne CH, Grayson BH.Lengthening the human mandible by gradual distraction:PlastReconstrSurg1992;89: 1-8.
- [24]. Molina F, Ortiz MonasterioF.Mandibular elongation and remodeling by distraction. A farewell to major osteotomies:PlastReconstrSurg 1995; 96:825-842.
- [25]. George K.B. Sa'ndor et al Distraction Osteogenesis of the Midface Oral Maxillofacial SurgClin N Am 17 (2005)
- [26]. Subodh Shankar Natu et al The biology of distraction osteogenesis for correction of mandibular
- [27]. andcranioaxillofacial defects: A review Dental Research Journal / January 2014
- [28]. Bell WH, Harper RP, Gonzalez M, et alDistraction Osteogenesis to Widen the Mandible.. Br J Oral MaxillofacSurg 35:11, 1997
- [29]. Kole h surgical operation on the alveolar ridge to correct occlusalabnormalities.Oralscie.oral Med. Oral pathol.1959,12(5):515-29
- [30]. G. Swennen, R. Dempf, H. Schliephake: Cranio-facial distraction osteogenesis: a
- [31]. review of the literature. Part II: experimental studies. Int. J. Oral Maxillofac.Surg.
- [32]. 2002; 31: 123–135
- [33]. Michieli .S ,MiottiB.Lengthening of mandibular body by gradual surgical orthodontic distraction J oral surg 1977 Mar (3)187-92
- [34]. N.Maffulli Biology of tendon injury :healing ,modeling and remodeling J Musculoskelet Neuronal interact 2006;6(2):181-190
- [35]. Aronson I et al The hystology of Distraction Osteogenesis using different external fixators .Clinorthoprelat Res 1989.33:246-250
- [36]. Schenk and Gachter et al Expressionn of BMP-4 Mrna during distraction osteogenesis in rabbits Act OrthopScand1998 :69(4);420-425
- [37]. Tajana et al Bone formation after distraction osteotomy of the radius in sheep .Acta.OrthopScand 1992 63 (6)599-603
- [38]. Yoshiki Hamada et al Backward distraction osteogenesis of condylar segment in patient with
- [39]. mandibular ramus deficiency—Report of a case Oral Surg Oral Med
- [40]. V. Bansal, S. Singh, N. Garg, P. Dubey: Transport distraction osteogenesis as a method of reconstruction of the temporomandibular joint following gap arthroplasty for post-traumatic ankylosis in children: a clinical and radiological prospective assessment of outcome. Int. J. Oral Maxillofac. Surg. 2014; 43: 227–2
- [41]. T. H. El-Bialy, Y. Rzdolsky, N. D. Kravitz, S. Dessner, R. F. Elgazzar: Long-term results of bilateral mandibular distraction osteogenesis using an intraoral toothborne device in adult Class II patients. Int. J. Oral Maxillofac.Surg. 2013 36. # 2013
- [42]. K. Ueki, K. Marukawa, K. Nakagawa, E. Yamamoto: Multidirectional distractionosteogenesis for Crouzon syndrome: technical note. Int. J. Oral Maxillofac. Surg.2005; 34: 82–84. # 2004 International Association of Oral and Maxillofacial

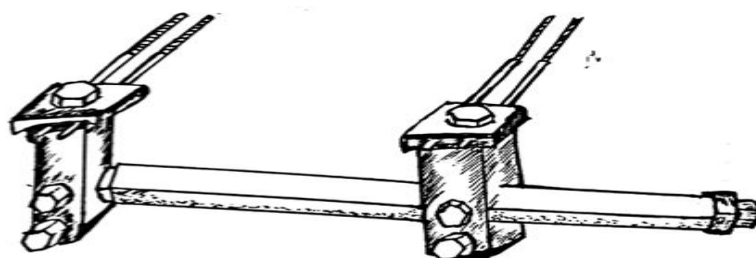


Fig-1 Hoffman Mini Lengthener

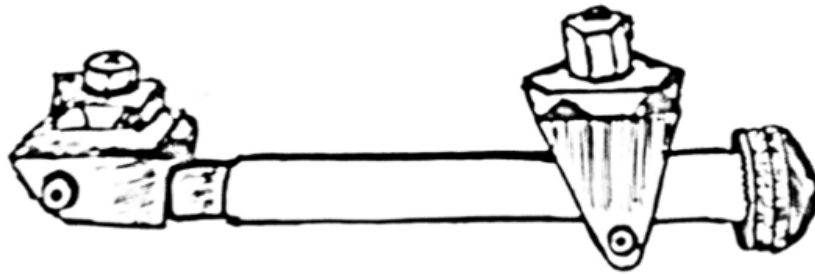


Fig. 2 Synthes Mini lengthening Apparatus

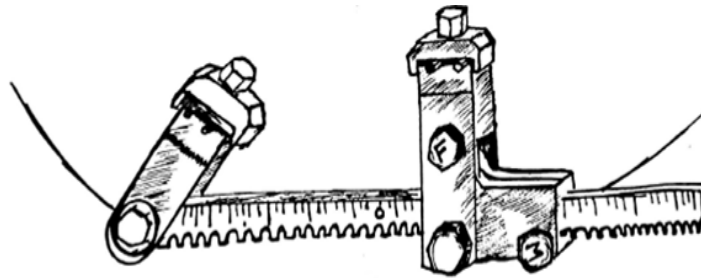


Fig. 3 Unidirectional Mandibular Distraction Device

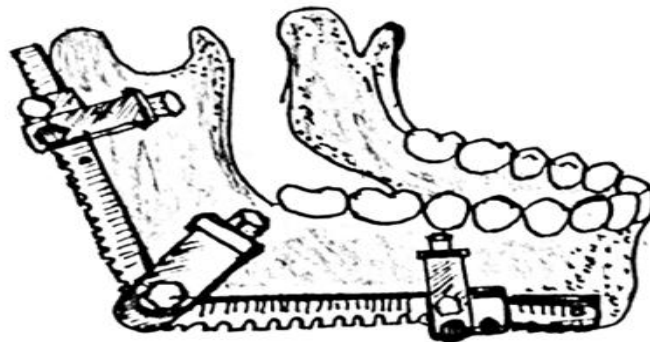


Fig. 4 Normal Bidirectional Distractor

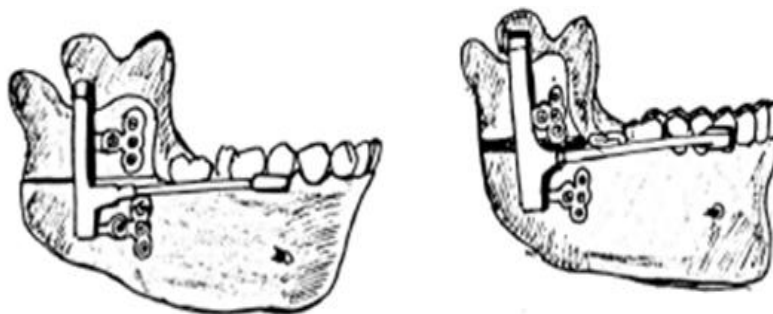

Fig. 5 Wangerin Mandibular Distraction

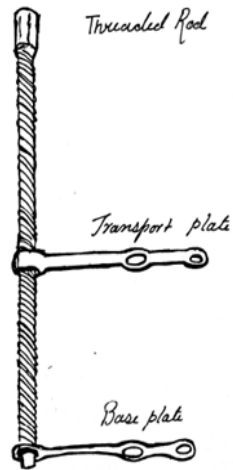


Fig. 6 Lead System for Endosseous Distraction of Alveolar Ridge

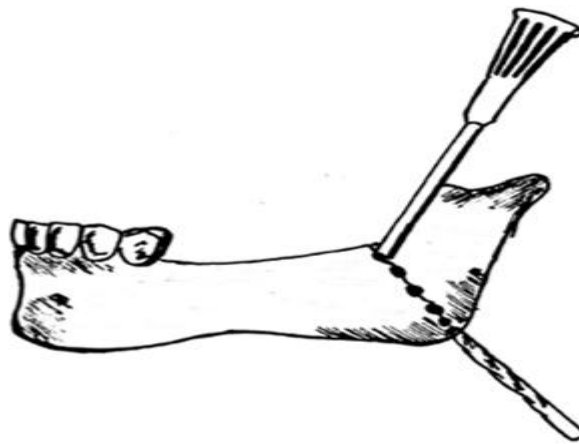


Fig. 7 McCarthy's Osteotomy Technique